DENTISTRY

Visibility of Mandibular Canal on CBCT Cross-Sectional Images in Comparison with Panoramic Radiograph: Retrospective Study

Resha Jameel Abdulsaheb[1], Areej Ahmed Najm[2], Firas Abdulameer Farhan[3]

ABSTRACT

Objective: **Detection of the mandibular canal (MC) is an important requirement for different surgical procedures such as implant placement, surgical removal of the pathological lesion and even tooth extraction. Orthopantomogram (OPG) and cone-beam computed tomography (CBCT) represent an advanced imaging technology, but distinguishing the MC from surrounding structures may be difficult.**

Design: **This cross-sectional study was conducted to assess the visibility of MC in different regions using CBCT and OPG images and compare between them, also to compare the results between male and female patients.**

Material and Methods: **In this study 400 hemi mandible (100 males and 100 females) were examined by CBCT cross-section and compared to digital panoramic images. The images were evaluated and the MC visibility was assessed in four regions (second premolar, first molar, second molar and distal to the second molar) and classified into a clear and unclear score. The collected data were statistically analyzed to assess the significant differences between regions, gender and imaging technique.**

Results: **The MC recognition by CBCT was better than OPG images and showed a significant difference. The percentage of MC visibility by CBCT was higher in the premolar region (65%) and decreased posteriorly while by OPG the higher percentage was in the third molar region (73%). There were no significant differences in MC visibility between males and females.**

Conclusion: **CBCT is the best imaging technique that provides cross sectional visualization of the MC, and bone morphology prior to any surgical procedure including dental implant.**

KEY WORDS

mandibular canal, cone-beam computed tomography (CBCT), orthopantomograph (OPG)

INTRODUCTION

The mandibular canal (MC) or the inferior alveolar canal naturally extends from the mandibular foramen to the mental foramen and includes the inferior alveolar artery, vein and the inferior alveolar nerve. The MC is a significant anatomical structure and an important requirement for pre-operative planning of surgical procedures such as bilateral sagittal split osteotomy, endosteal implant placement, mandibular angle plasty, third molar removal, root canal treatment, and apical surgery to minimize the possible complications during surgery[1-3].

The determination of the location of MC is considered to be a critical issue that may affect the treatment plan and the visualization of the MC is an important requirement for surgical procedures especially dental implants. Radiographical examination using panoramic radiograph (OPG) offers a diagnostic tool to localize MC, however, it is not considered to be an accurate tool; because it is a two-dimensional image that can be affected by tissues and structures overlapping. In recent years, maxillofacial cone beam computerized tomography (CBCT) has been widely used in most dental treatments as an initial examination method utilized a three-dimensional technique. CBCT facilitates the localization of significant anatomic structures and provides data concerning bone morphology[4,5].

CBCT is an important dental diagnostic imaging modality that employs a cone or pyramidal-shaped beam to obtain multiple projections in a single rotation. It represents an advanced technology, but distinguishing the MC from surrounding structures may be difficult and it depends on the operator's experience[6].

The aims of this study were to assess the visibility of the MC in different regions in the posterior mandible starting from the second premolar and extending posteriorly to second molar teeth, by utilizing CBCT cross-sectional images in comparison with OPG images, also to compare the results between male and female patients.

MATERIAL AND METHODS

The study sample consisted of 200 CBCT images (100 females and 100 males) retrieved from the archives of the CBCT unit of a private radiology clinic in Baghdad, the images were selected and examined by specialized maxillofacial radiologists.

Received on March 31, 2021 and accepted on April 30, 2021

1) Assistant lecturer, Department of Oral and Maxillofacial Radiology, College of Dentistry, University of Baghdad Iraq
2) Assistant Professor, in Oral and Maxillofacial Radiology, College of Dentistry, University of Baghdad Iraq
3) Lecturer, University of Malaysia UM, Department of Prosthodontics, College of Dentistry, University of Baghdad Iraq
Correspondence to: Resha Jameel Abdulsaheb
(e-mail: dr.rasha.jameel1400@codental.uobaghdad.edu.iq)

© 2021 Japan University of Health Sciences
& Japan International Cultural Exchange Foundation

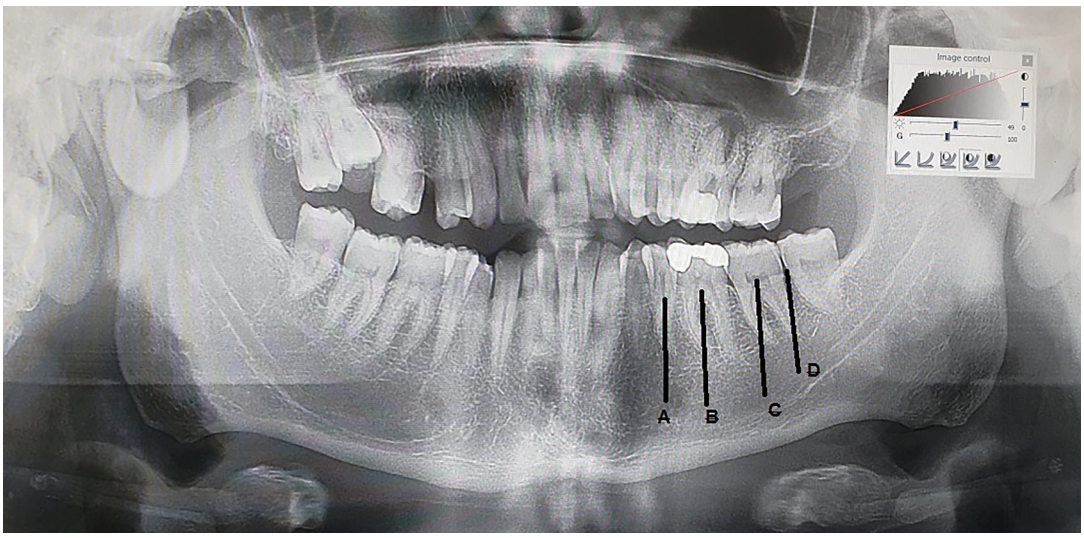

Figure 1: Panoramic image shows the divisions areas of the mandible

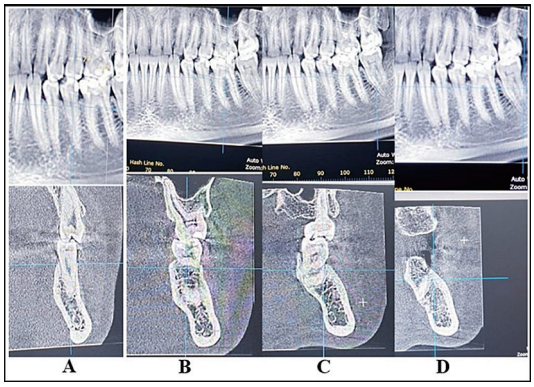

Figure 2: Reconstructed panorama with cross-sectional images show the division areas of the mandible (A, B, C and D)

These images were taken with a digital panoramic and CBCT system (SORDAX, Finland) under standard exposure factors (parameters). The selection of patients age was above 17 years old, totally 400 hemi-mandible were examined by cross-sectional views of CBCT and panoramic radiograph of the same patient by using CBCT imaging software (OnDemand3D™ Cybermed Inc. Finland) and for panoramic image using (SCANORA software, Finland). The images were selected according to following criteria:

1- Good image quality.
2- No pathological lesion and fracture of the mandible.
3- No implant and missing teeth in the posterior part of the mandible except the third molar.

The readings were achieved at different mandible regions; second premolar area (A), first molar area (B), second molar area (C) and distal to the second molar area (D) as shown in Figure 1 and 2.

To compare the visibility of MC according to the gender by CBCT and OPG; the samples were divided into; male and female.

These areas were organized and divided by using the dental software application and obtaining reconstructed panorama and cross-sectional views to optimize the center of each examined view. The observer repeated the reading 3 times with a one-week interval between each reading, each observer worked separately, and compared the results to each other.

The visibility of the MC in CBCT and OPG, determined by the ability of the observer to differentiate the MC from the surrounding bone, was registered as either clear (C) or unclear (UC). The data of each examined area were clustered together and the visibility was compared according to the imaging modality (CBCT and OPG) and according to gender (male and female) using CBCT.

The collected data were analyzed statistically by Graph Pad software program by using Chi -square to assess the statistically significant differences between groups.

RESULTS

The visibility of MC in region A by CBCT was clearer than OPG, while in region B the visibility was better using OPG (conversely). The details are shown in Tables 1 and 2 and Figures 3 and 4.

The statistical analysis showed there were significant differences between CBCT and OPG images at the region A, B and D while at the region C there was a non-significant difference as shown in Table 2.

The visibility of MC by CBCT in males and females showed that males had higher visibility of the canal compared to female (represented by bar chart below).

DISCUSSION

This study is the first one in Iraq that is concerned with the MC visibility by CBCT in comparison with OPG. The MC is a significant anatomical structure and fundamental requirement for preoperative planning of surgical procedures involving the posterior mandible to minimize the possible complications during surgery.

In this study, detection of the MC course was assessed by using two types of imaging modalities; CBCT and panoramic radiograph. The results have presented the difference in the clearance of canal visibility throughout the normal anatomical landmarks. The new CBCT imaging technologies have allowed the investigation of anatomical structures in different views without image overlapping or misdiagnosis with other structures (such as bone marrow). CBCT is a providing technique for the detailed diagnosis of bony anatomical landmarks, with good resolution as compared with OPG and low radiation dose as compared with CT scan[7-9].

Oliveira-Santos *et al* in 2011 performed a study to assess the visibility of MC by CBCT and reported that the visibility increased with moving posteriorly (distal to mental foramen). The disagreement with this study may be due to the small sample size used by the authors or the different analytical methods[10].

Jung and Cho in 2014 found that visibility of MC by CBCT was better than by OPG and the visibility of the canal was decreased by moving further posteriorly. This disagreed with the results of the current study which may be due to using different measurement techniques or patient age because bone loses density and trabeculation as a result of the lost minerals when the patient grows older[11].

The results of the present study showed less percentage for MC visualization by OPG and this was agreed with Naitoh *et al* in 2009[12], Jung and Cho in 2014[11], and Lindh *et al* in 1989[13]. CBCT reported superior results as compared to OPG for the identification of the MC, which is in line with Kamrun *et al* in 2013[14] who confirmed that the visibility

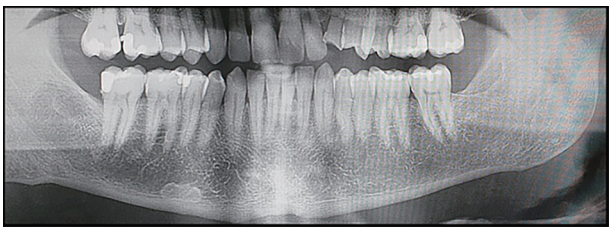

Figure 3: Panoramic image show unclear MC at 2nd premolar, 1st and 2nd molar area for both sides

Figure 4: Panoramic image show clear MC at 1st and 2nd molar area and unclear MC at 2nd premolar area for both sides.

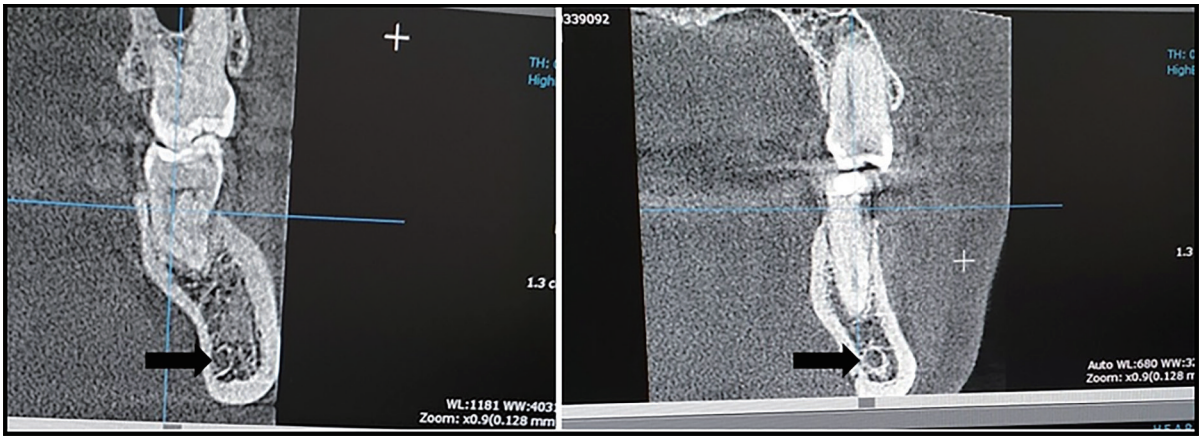

Figure 5: Cross-sectional image show clear MC at 1st molar and 2nd premolar area (black arrow)

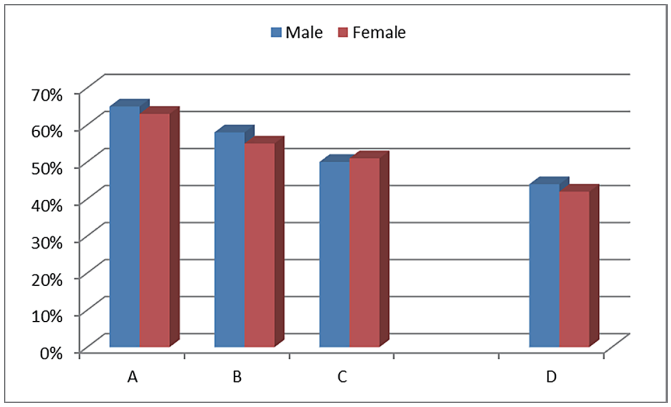

Figure 6: Comparison of MC visibility between male and female by CBCT

Table 1: Percentage of mandibular canal visibility according to the regions by OPG and CBCT

Type of x-ray	Regions			
	A	B	C	D
OPG	23%	46%	51%	73%
CBCT	65%	56%	47%	42%

Table 2: comparison of mandibular canal visibility (in the 4 regions) between CBCT and OPG (by using chi-square test)

Area	Degree of visibility	CBCT		OPG		T-test
		N	%	N	%	
A	C	273	91	220	73.3	P < 0.0001
	UC	27	9	80	26.6	S
B	C	256	85.3	223	74.3	0.0011
	UC	44	14.6	77	25.6	S
C	C	173	57.6	178	59.3	0.7403
	UC	127	42.3	122	40.6	NS
D	C	134	44.6	125	41.6	0.5096
	UC	166	55.3	175	58.3	NS

(S = significant, NS = non-significant)

of cross-sectional CT images was significantly higher than that of panoramic images of the MC.

In the present study, the MC was more clearly visible in the anterior part of mandible than the posterior part when using CBCT cross-sectional images. The visibility of MC was become less clear when directed towards the posterior teeth. These findings disagreed with the previously mentioned studies that found more clear visibility of MC in posterior part of mandible[15] and disagreed with the results of OPG in the same study. This difference may be due to that previous studies did not use CBCT therefore they did not reach clear radiographic visibility of the MC near the mental foramen due to the lack of definite walls in the anterior portion of the canal[16].

This study exhibited the importance of CBCT to clarify the MC and considered as a precise procedure as compared with OPG especially in the mental area, which indicates the ability of CBCT to visualize and diagnose superimposed anatomical landmarks of the oral and maxillofacial region. It is considered a suitable diagnostic tool for the visualization of the MC route because this structure appears to be related to the bone density of canal walls and its visibility was dependent on the canal anatomic features than on the imaging technique[17]. Thus, the degree of detection difficulty might be expected when imagining the MC by other visualization modalities[18].

CONCLUSION

The MC visibility on CBCT cross-sectional images is better than

that in OPG. However, the visibility of the canal from its surroundings became less clear towards the posterior region of the mandible. The results showed a significant difference between the two imaging techniques with more clearance and visibility of the MC by CBCT. Differences in the visibility of the mandibular on CBCT cross-sectional images between male and female patients were statistically non-significant.

REFFERENCES

1. Kim TS, Caruso JM, Christensen H, Torabinejad M. A comparison of cone-beam computed tomography and direct measurement in the examination of the mandibular canal and adjacent structures. J Endod 2010; 36(7): 1191-4
2. Akbulut N, Akbulut S, Oztas B, Kursun S, Soylu E, Guven O. importance of bifid mandibular canal in implantology and in oral surgery: review of the literature and report of three cases. Cumhuriyet Dent J. 2017; 20(3): 198-203
3. Libersa P, Savignat M, Tonnel A. Neurosensory disturbances of the inferior alveolar nerve: a retrospective study of complaints in a 10-year period. J Oral Maxillofac Surg. 2007; 65(8): 1486
4. Boeddinghaus R, Whyte A. Current concepts in maxillofacial imaging. Eur J Radiol. 2008; 66(3): 396-418.
5. Tantanapornkul W, Okouchi K, Fujiwara Y, Yamashiro M, Maruoka Y, Ohbayashi N. A comparative study of cone-beam computed tomography and conventional panoramic radiography in assessing the topographic relationship between the mandibular canal and impacted third molars. Oral Surg Oral Med Oral Pathol Oral Radiol endod. 2007; 103: 253-259.
6. Ziegler CM, Woertche R, Brief J, Hassfeld S. Clinical indications for digital volume tomography in oral and maxillofacial surgery. Dentomaxillofac Radiol J. 2002; 31: 126-130.
7. Wadu SC, Penhall B, Townsend GC. Morphological variability of the human inferior alveolar nerve. Clin Anat. 1997; 10: 82-87.
8. Kamburoglu K, Kiliç C, Özen T, Yüksel SP. Measurements of mandibular canal region obtained by cone-beam computed tomography: a cadaveric study. Oral Surg Oral Med Oral Pathol Oral Radiol endod. 2009;107: e34-e42
9. Denio D, Torabinejad M, Bakland LK. Anatomical relationship of the mandibular canal to its surrounding structures in mature mandibles. J Endod. 1992; 18: 161-165.
10. Oliveira-Santos C, Capelozza AL, Dezzoti MS, Fischer CM, Poleti ML, Rubira-Bullen IR. Visibility of the mandibular canal on CBCT cross-sectional images. J Appl Oral Sci. 2011; 19(3): 240-3.
11. Jung YH, Cho BH. Radiographic evaluation of the course and visibility of the mandibular canal. Imaging Sci Dent. 2014; 44(4): 273-278.
12. Naitoh M, Katsumata A, Kubota Y, Hayashi M, Ariji E. Relationship between cancellous bone density and mandibular canal depiction. Implant Dent. 2009; 18: 112-118.
13. Lindh C, Petersson A. Radiologic examination for location of the mandibular canal: a comparison between panoramic radiography and conventional tomography. Int J Oral Maxillofac Implants. 1989; 4: 249-253.
14. Kamrun N, Tetsumura A, Nomura Y, Yamaguchi S, Baba O, Nakamura S, *et al*. Visualization of the superior and inferior borders of the mandibular canal: a comparative study using digital panoramic radiographs and cross-sectional computed tomography images. Oral Surg Oral Med Oral Pathol Oral Radiol. 2013; 115: 550-557.
15. Anderson LC, Kosinsk TF, Mentag PJ. A review of the intraosseous course of the nerves of the mandible. J Oral Implantol. 1991; 17: 394-403.
16. Liang X, Jacobs R, Hassan B, Li L, Pauwels R, Corpas L, *et al*. A comparative evaluation of Cone Beam Computed Tomography (CBCT) and Multi-Slice CT (MSCT). Part I. On subjective image quality. Eur J Radiol. 2010; 75(2): 265-269.
17. Scarfe WC, Farman AG, Sukovic P. Clinical applications of cone-beam computed tomography in dental practice. J Can Dent Assoc. 2006; 72: 75-80.
18. Angelopoulous C, Thomas SL, Hechler S, Parissis N, Hlavacek M. Comparison between digital panoramic radiography and cone-beam computed tomography for the identification of the mandibular canal as part of presurgical dental implant assessment. J Oral Maxillofac Surg. 2008; 66: 2130-2135.